

# Rethinking Antenatal Breastfeeding Education

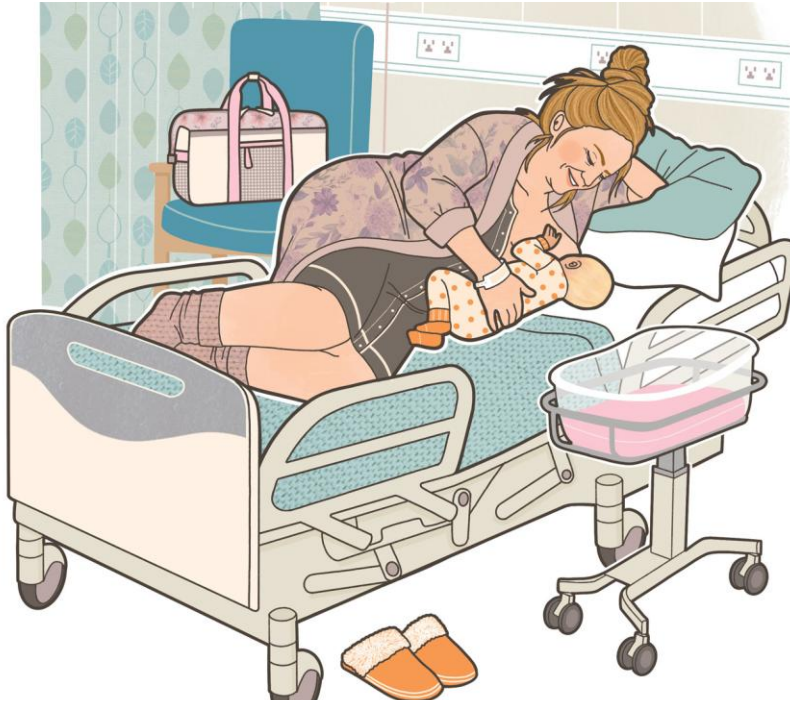Presenter: Caoimhe Whelan



1

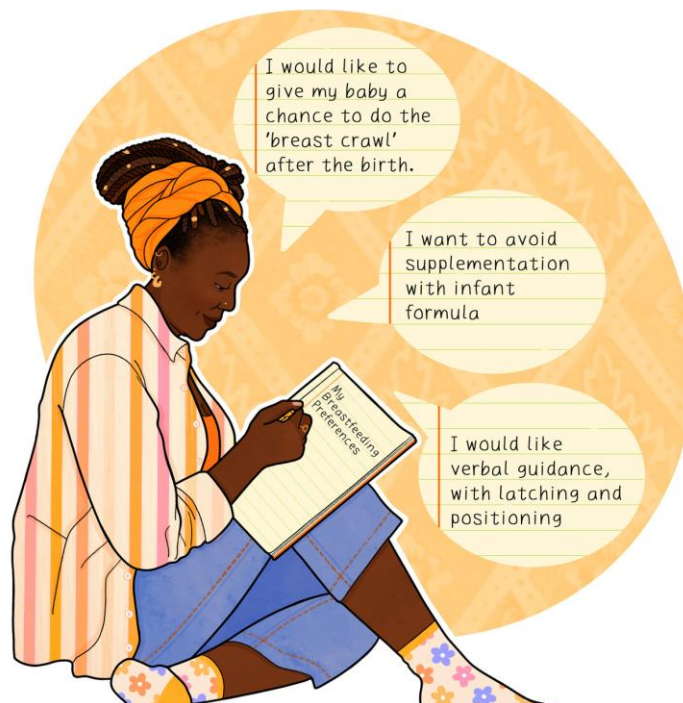

2



©Caoimhe Whelan2025

3



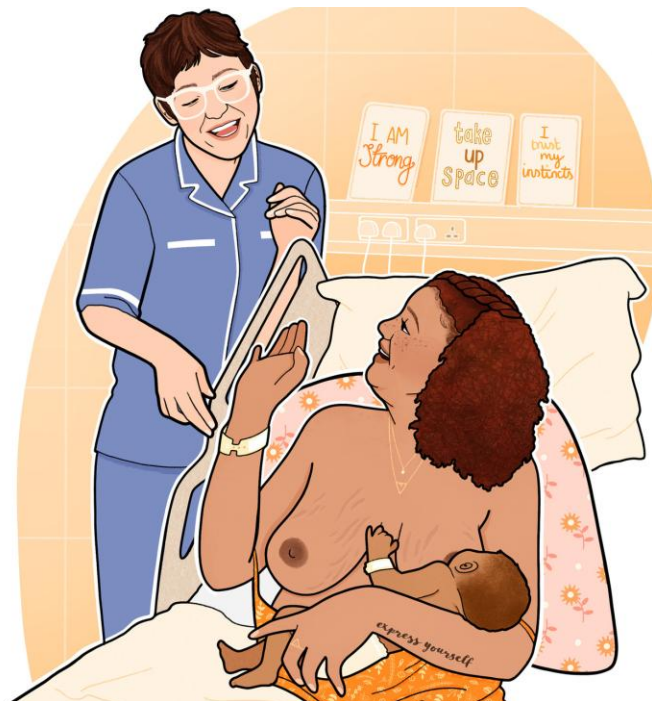©Caoimhe Whelan2025

4



©Caoimhe Whelan2025

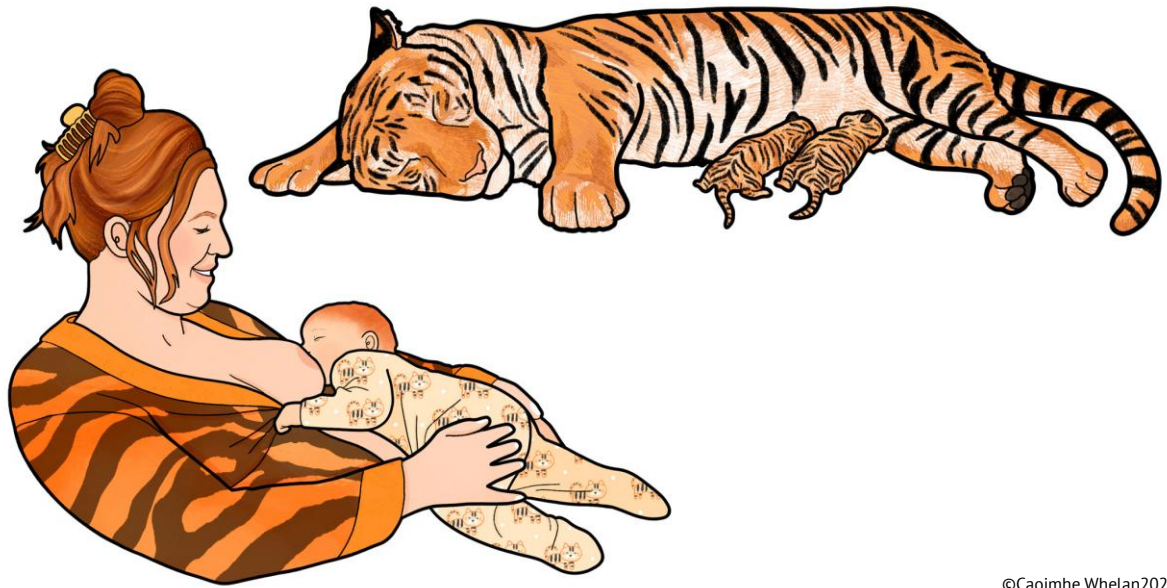5



©Caoimhe Whelan2025

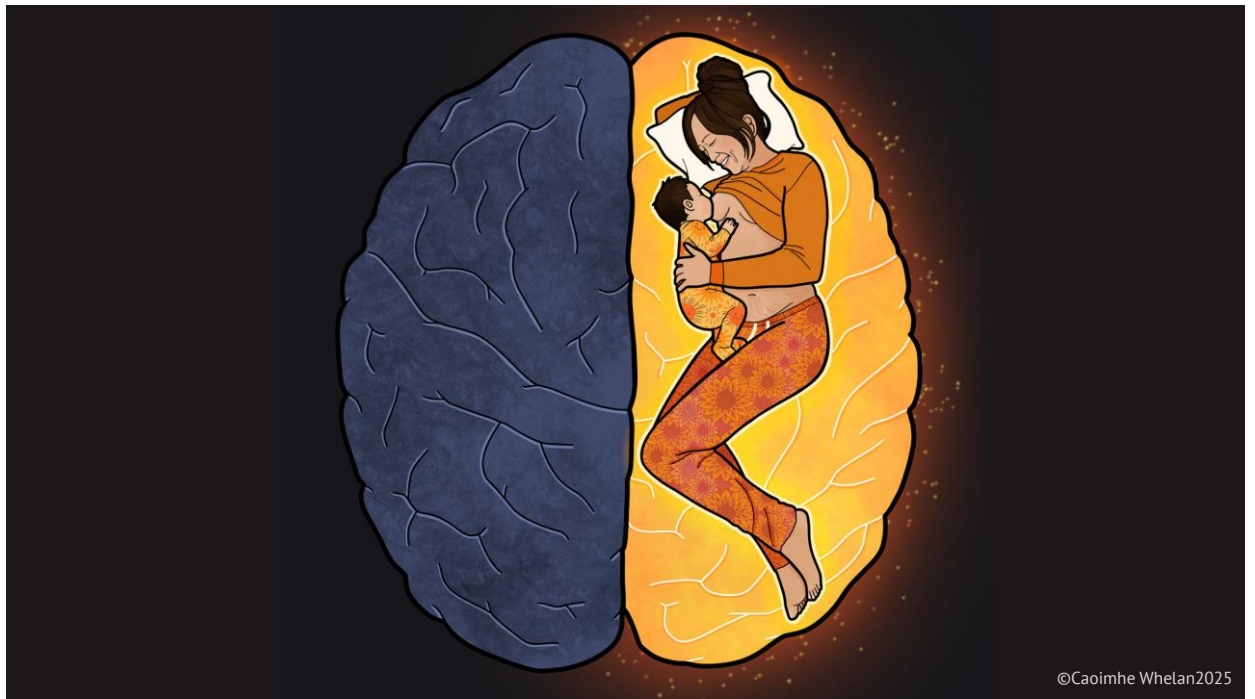6





©Caoimhe Whelan2025

7



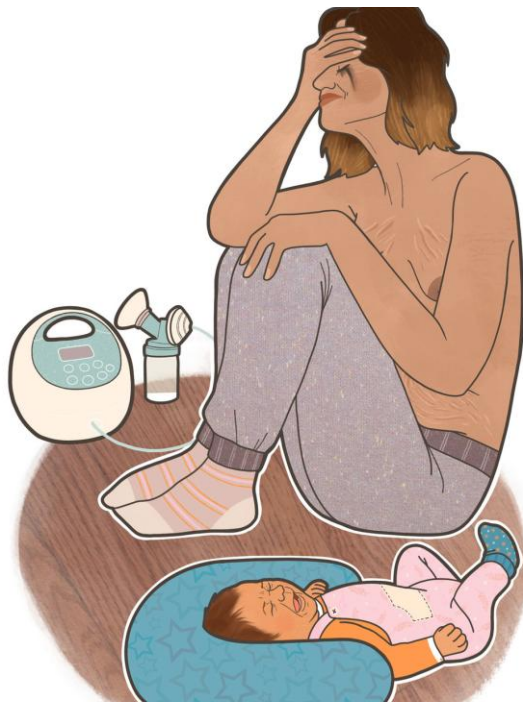©Caoimhe Whelan2025

8



©Caoimhe Whelan2025

9

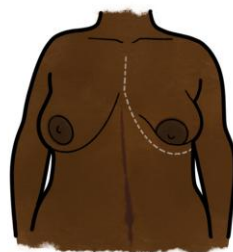

©Caoimhe Whelan2025

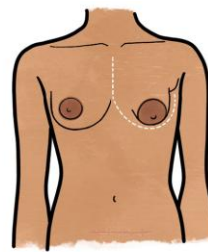
10



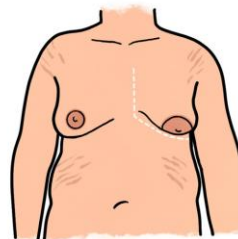
11



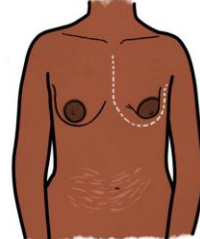
**TYPE 1**  
hypoplasia of the  
lower medial quadrant



**TYPE 2**  
hypoplasia of the  
lower and lateral quadrant  
sufficient skin in the subareolar region



**TYPE 3**  
hypoplasia of the lower  
medial and lateral quadrant  
Skin deficiency in the subareolar region



**TYPE 4**  
severe breast constriction  
minimal breast base

©Caoimhe Whelan2025

12



©Caoimhe Whelan2025

13

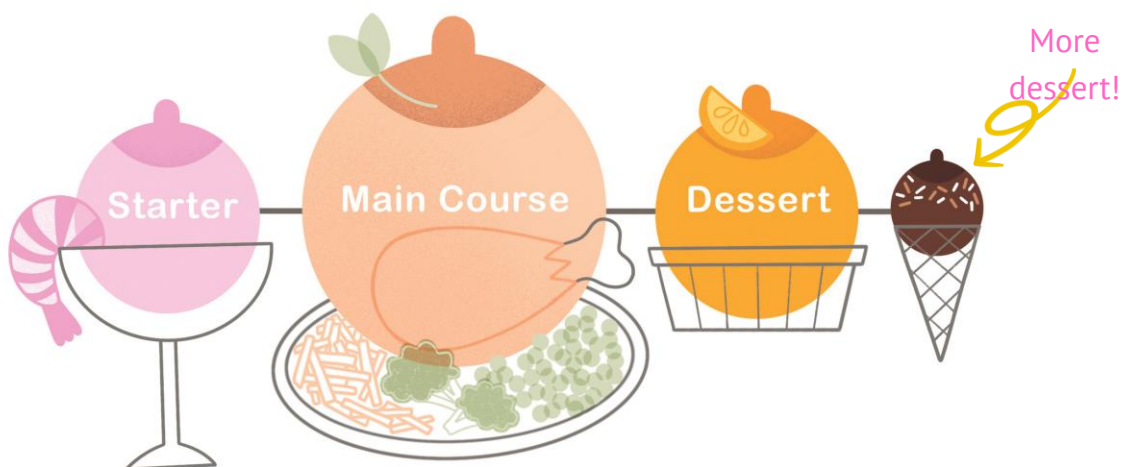


Image from 'Practical Breastfeeding: An Illustrated Guide for Parents'

©Caoimhe Whelan2025

14





15

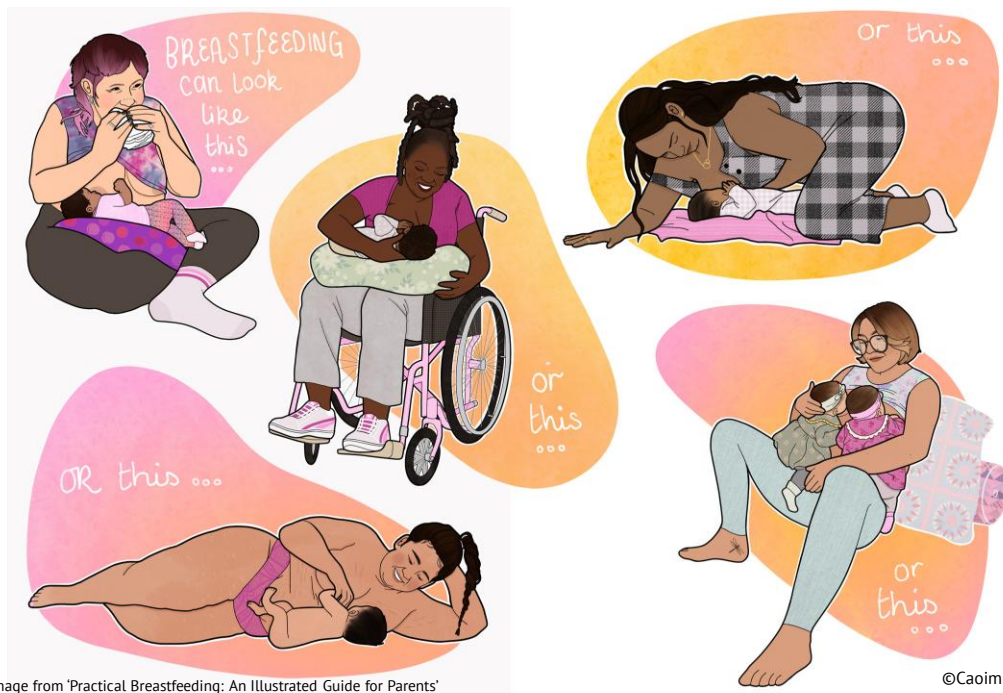


Image from 'Practical Breastfeeding: An Illustrated Guide for Parents'

16





©Caoimhe Whelan2025

17



©Caoimhe Whelan2025

18



Image from 'Practical Breastfeeding: An Illustrated Guide for Parents'

©Caoimhe Whelan2025

19



Image from 'Practical Breastfeeding: An Illustrated Guide for Parents'

©Caoimhe Whelan2025

20